

CLINICAL IMAGE OF THE MONTH

Case 2. Leiomyosarcoma of the inferior vena cava revealed by lower extremities edema



Caso 2. Leiomiosarcoma de vena cava inferior y edema de extremidades inferiores

M. Mahmoud*, M.B. Messaoud, H. Riahi, O. Azaiz

Medical Imaging Department La Rabta, Tunis El Manar University, Tunis, Tunisia

Received 14 January 2014; accepted 27 February 2014

Available online 10 May 2014

Case report

A 43-year-old woman consulted for bilateral lower extremities edema. Questioning revealed abdominal pain, asthenia, anorexia and weight loss of 6 months duration. An abdominal iodine enhanced CT scan was realized and revealed a large solid mass as shown in [Figs. 1 and 2](#).

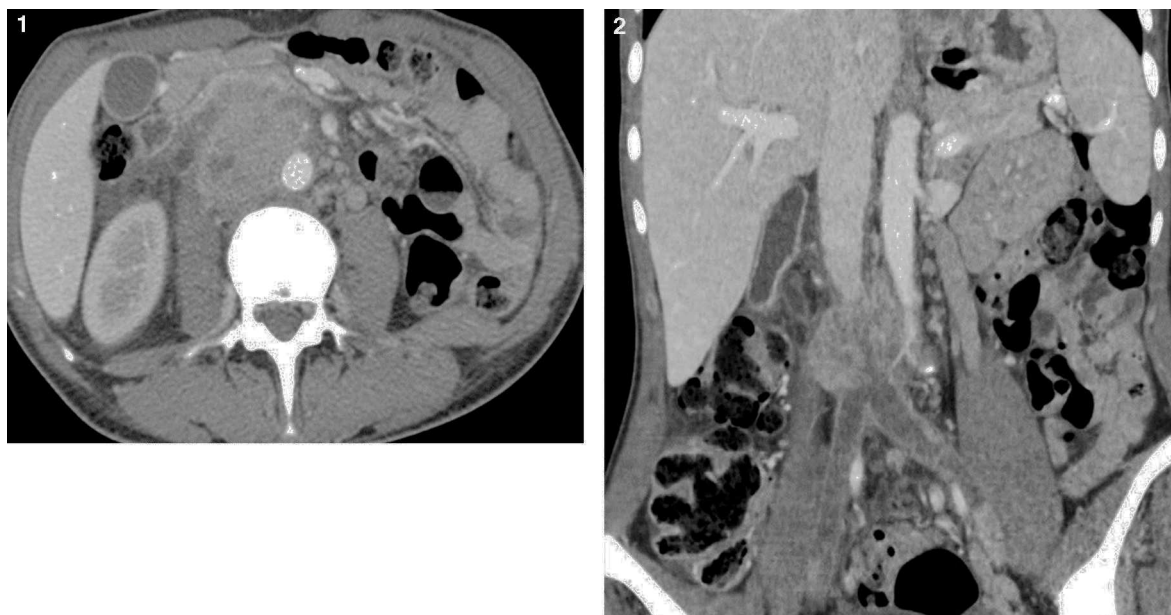
Question:

What is your diagnosis?

- Pheochromocytoma
- Leiomyosarcoma of the inferior vena cava
- Lymphadenopathy
- Gastro-intestinal stromal tumor (GIST)

* Corresponding author.

E-mail address: Mahmoud.maha@gmail.com (M. Mahmoud).



Figures 1 and 2 Abdominal CT scan (axial and frontal). Heterogeneous retroperitoneal solid mass centered in the inferior vena cava (IVC) infrarenal. Iliac vein thrombosis seen. Invasion of the lumbar segment of the ureter and psoas muscle picture, being in contact with the spine. Forward, contact the third duodenal portion. The supra-renal IVC is permeable.