

**Pseudooclusión carotídea
hemodinámica secundaria a
estenosis sincrónica de arteria
carótida común y carótida
interna**

**Hemodynamic carotid pseudo-
occlusion due to synchronic
common and internal carotid
artery stenosis**

10.20960/angiologia.00708

04/11/2025

Hemodynamic carotid pseudoocclusion due to synchronic common and internal carotid artery stenosis

Pseudooclusión carotídea hemodinámica secundaria a estenosis sincrónica de arteria carótida común y carótida interna

René Romero Sarmiento, Ignacio Michel Guisasola, José A. González-Fajardo

Angiology, Vascular Surgery and Endovascular Department.
Radiological Interventional Unit. Hospital Universitario 12 de Octubre.
Madrid, Spain

Correspondence: René Romero Sarmiento. Angiology, Vascular Surgery and Endovascular Department. Hospital Universitario 12 de Octubre. Avda. de Córdoba, s/n. 28041 Madrid, Spain
e-mail: reneromero1991@hotmail.com

Received: 11/7/2024

Accepted: 11/11/2024

Conflicts of interest: the authors declared no conflicts of interest.

Artificial intelligence: the authors declare that they did not used any artificial intelligence (AI) or AI-assisted technologies to write this the article.

ABSTRACT

Introduction: synchronic stenosis of the common and internal carotid artery is a rare condition that behave as a hemodynamic pseudoocclusion of the intracranial carotid artery.

Case report: we report an unusual case of a patient with right common and internal carotid symptomatic stenosis who was diagnosed with carotid artery occlusion. Careful review of the AngioCT and arteriogram showed that in tandem stenosis of the common and

internal stenosis can mimic an occlusion of the proximal portion of the internal carotid artery with alternating blood flow.

Discussion: after placing a stent in the common carotid artery the stenosis of the internal carotid artery was modified to 60 % and a normalization of the cerebral perfusion was shown.

Keywords: Innominate artery. Stenosis. Alternating blood flow. Stent. Common carotid artery.

RESUMEN

Introducción: la estenosis sincrónica de la arteria carótida común y de la interna es una patología poco frecuente que se comporta como una pseudooclusión a nivel de la arteria carótida intracraneal.

Caso clínico: presentamos el caso poco común de un paciente con estenosis de arteria carótida común e interna derecha que fue diagnosticado de oclusión carotídea a nivel intracraneal. Una revisión cuidadosa de la angio TAC y de la arteriografía demostró que las lesiones en tándem de la arteria carótida común e interna pueden comportarse como una oclusión en la porción proximal de la carótida interna con flujo alternante.

Discusión: Después de colocar un *stent* en la arteria carótida común, no solo se modificó el grado de estenosis de la arteria carótida común al 60 %, sino que se consiguió la normalización de la perfusión cerebral.

Palabras claves: Arteria innominada. Estenosis. Flujo alternante. Stent. Arteria carótida común.

INTRODUCTION

In contrast to isolated internal carotid artery (ICA) stenosis, synchronic common (CCA) and internal carotid stenoses can behave

as a hemodynamic pseudoocclusion of the artery and mimic a greater stenosis of the ICA. We report an unusual case of this condition.

CASE REPORT

A 53-year-old male, smoker and dyslipemic, was admitted to the hospital with left brachio-fascial palsy TIA. CT-scan showed mixed atheromatous disease of the right CCA and an ipsilateral $> 90\%$ ICA stenosis (Figs. 1 and 2).

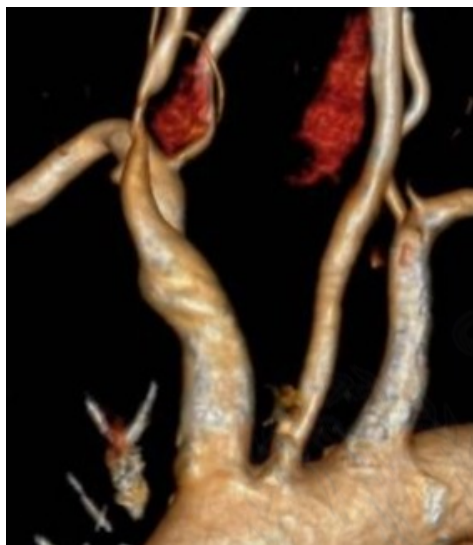

Figure 1. CT reconstruction: Right common carotid stenosis.

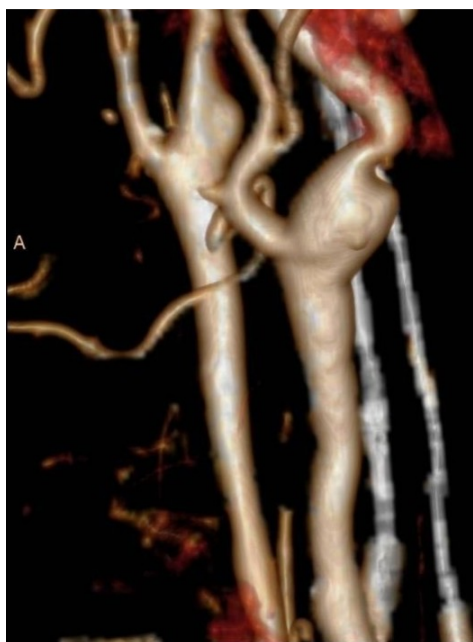

Figure 2. CT reconstruction: Right internal carotid stenosis.

The doppler US (DUS) demonstrated that the stenosis of the right CCA caused an acceleration over 330 cms/s but the one on the ICA caused an acceleration of 180 cm/s with a 2.4 ratio (1). A proximal near occlusive stenosis can actually decrease the acceleration corresponding to a significant carotid stenosis in the internal carotid artery (Figs. 3 and 4).

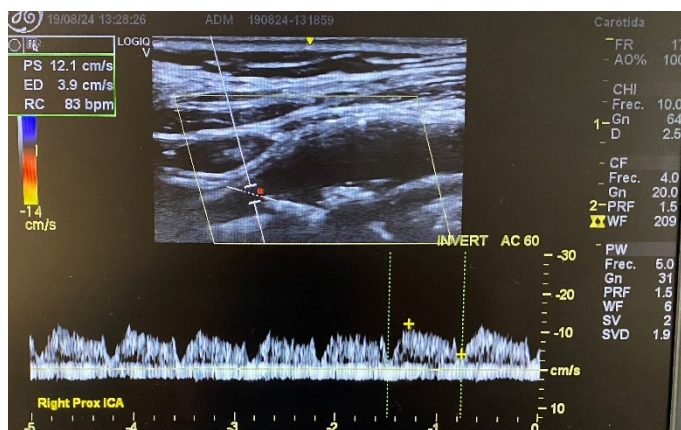
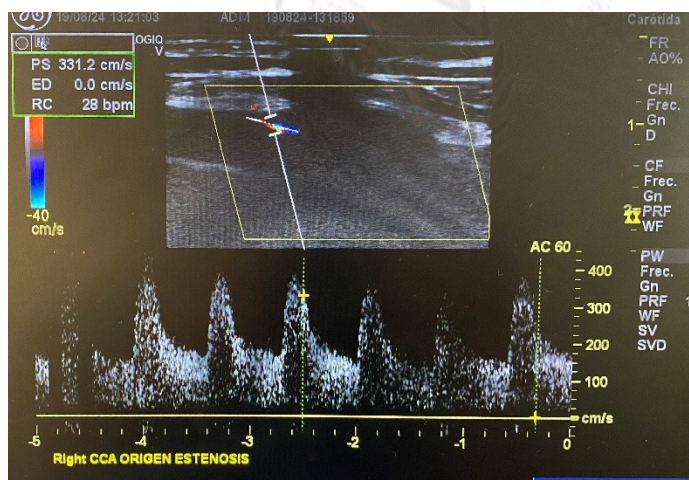
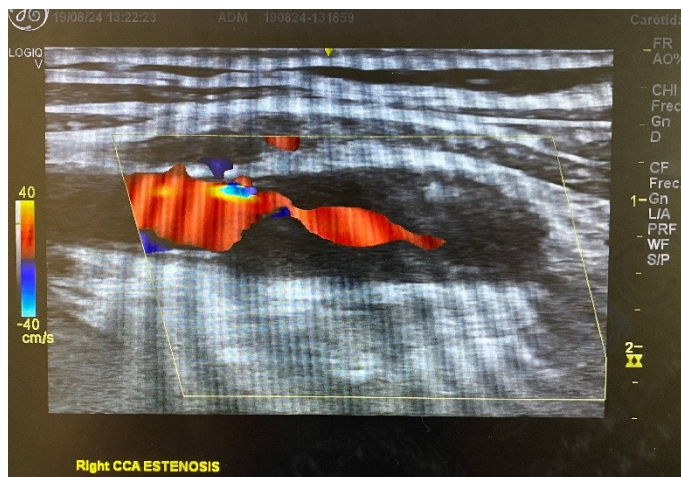

Figure 3. The first and second image shows the ICC stenosis with an acceleration up to 331.2 cm/s. The third image shows the tapered acceleration of the ICA due to the proximal stenosis.

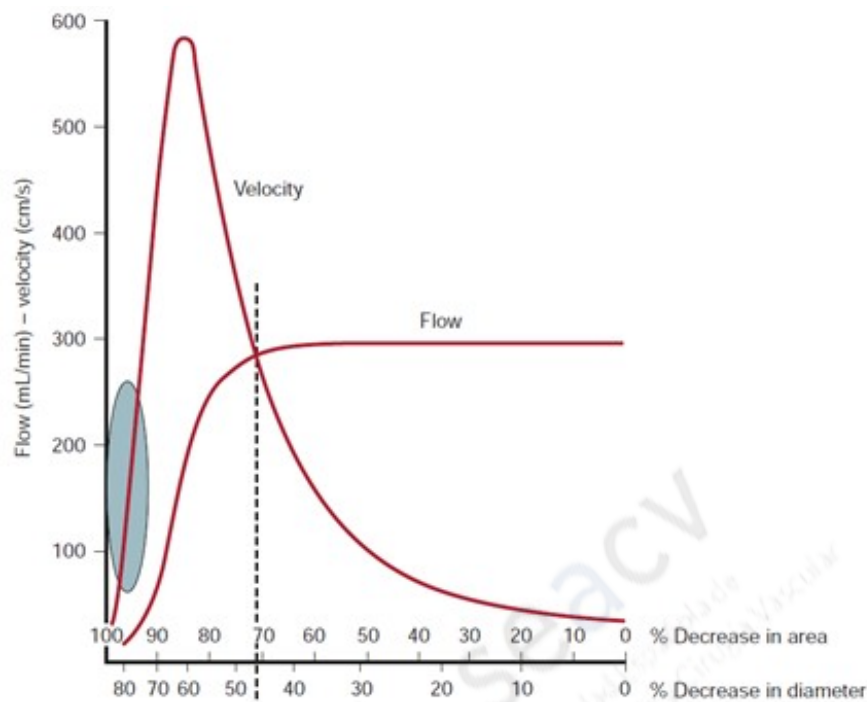


Figure 4. Correlation of percent diameter reduction with increases in blood flow velocity (cm/s). Note that a high-grade diameter-reducing stenosis causes volume flow to decrease toward zero, whereas the velocity within the stenosis may be minimally elevated (2).

Given these contradictory findings of the CT-scan and DUS, an angiogram was performed. It showed the already known stenoses and that the contrast didn't reach the cerebral perfusion. A closer look at the angiogram demonstrated an alternating image of the contrast in the intracranial portion of the ICA (Figs. 5 and 6).

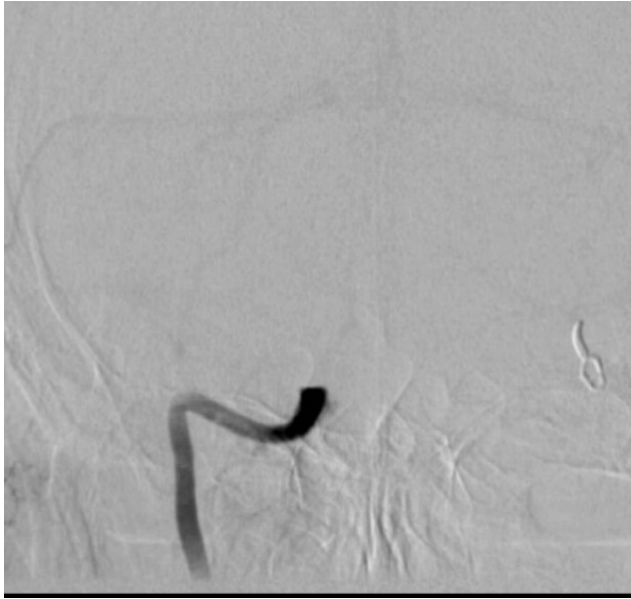

Figure 5. Angiogram: apparent occlusion of the intracranial portion of the internal carotid artery.

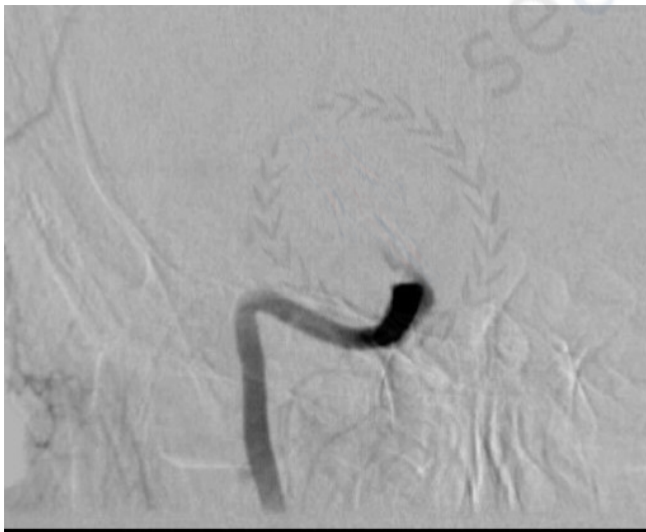

Figure 6. Angiogram: alternating imaging of contrast in the internal carotid artery.

This phenomenon occurs due to the hemodynamic effect of proximal carotid artery stenoses (3). Since the blood flow of the intracranial artery is tempered due to the stenosis, the pressure of the contralateral blood flow does not allow the contrast material to reach the circle of Willis, resulting in a pseudoocclusion. It also demonstrated

how a continuous significant stenosis can reduce the blood flowing through the ICA, show a lack of acceleration and ratio corresponding to the stenosis found on a CAT scan and behave as a suboclusive disease. We placed an 8 × 37 mm stent in the CCA (3) resulting in not only a normalization of the cerebral perfusion but also a reduction of the ICA stenosis to a 60 % one (Figs. 7 and 8).




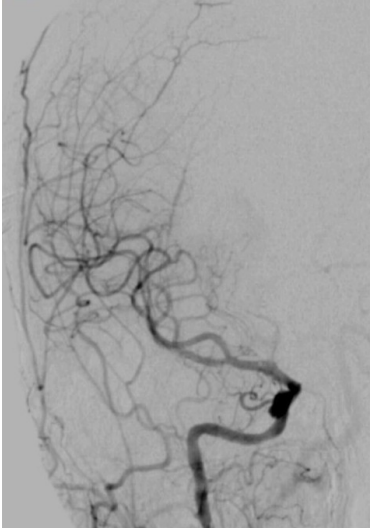
Initial angiogram	Stent placement and control
<div>A</div> 	<div>B</div> 
<div>C</div> 	<div>D</div> 

Figure 7. Stent placing and control. A. Common and internal carotid stenosis. B. Stent placing with improvement of internal carotid blood flow. C. Alternating contrast image before stent placement. D. Normalization of cerebral blood flow after stent placing.

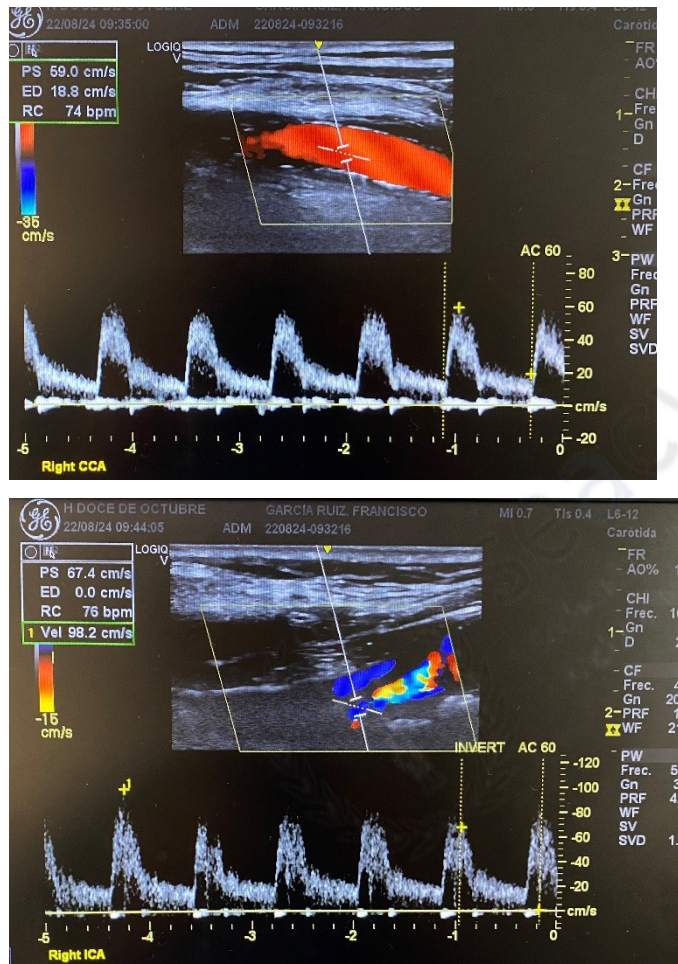


Figure 8. Doppler ultrasound control after CCA stent placing. Shows a patent stent with normalization of speed on the CCA and ICA.

DISCUSSION

Proximal carotid stenosis generating alternating blood flow of the intracranial circulation is a rare finding. It can mislead the diagnosis and affect the correct management of a patient with symptomatic carotid stenosis. López-Hernández et al (4). described a series of four patients with alternating flow in the anterior cerebral artery associated with innominate artery stenosis. Three patients presented with common carotid stenosis and one patient with innominate artery.

After successful angioplasties there was a normalization of orthograde flow in all cases. They also found that an early systolic hemodynamic compromise in the first segment of the anterior cerebral artery, in form of alternating flow, was an indirect indicator of ipsilateral proximal stenosis of the supraaortic arteries.

CONCLUSION

Synchronic CCA and ICA can mimic an increase the degree of stenosis of the ICA due to diminished blood flow and produce an image of pseudocclusion in the intracranial portion of the ICA. Treating the proximal lesion in the innominate or common carotid artery can not only reduce the degree of stenosis in the internal carotid artery but also reestablish normal ipsilateral intracranial blood flow.

BIBLIOGRAFÍA

1. Cucchiara BL. Evaluation of carotid artery stenosis. In: Kasner SE, Eidt JF, Mills JL (section editors) [accessed on October 30th, 2024]. Uptodate.com.
2. Stone AP, Ross MC. Vascular laboratory: Arterial Duplex scanning. In: Sidawy AN, Bruce AP (editors). Rutherford's vascular surgery and endovascular treatment. 10th ed. Elsevier - Health Sciences Division; 2023. p. 257
3. Naylor R, Rantner B, Ancetti S, De Borst GJ, De Carlo M, Halliday A, et. al. European society for vascular surgery (ESVS) 2023 clinical practice guidelines on the management of atherosclerotic carotid and vertebral artery disease. Eur J Vasc Endovasc Surg 2023;65(1):7-111. DOI: 10.1016/j.ejvs.2022.04.011.
4. López-Hernández N, García-Escrivá A, Ballenilla F, Gallego-León JI. Hemodynamic effects of proximal supra-aortic artery stenosis on anterior cerebral artery. Ultrasound Med Biol 2015 41(5):1488-92.

